Journal of Bone Oncology 34 (2022) 100428

Contents lists available at ScienceDirect

Journal of Bone Oncology

journal homepage: www.elsevier.com/locate/jbo

Joint-sparing reconstruction for extensive periacetabular metastases: Literature review and a novel minimally invasive surgical technique

Karla Teresa S. Araneta [b,*], Maroun Rizkallah [a], Louis-Martin Boucher [b], Robert E. Turcotte [a], Ahmed Aoude [a]

[a] Department of Orthopedic Surgery, McGill University Health Centre, Montreal, Canada
[b] Department of Diagnostic Radiology, McGill University Health Centre, Montreal, Canada

ARTICLE INFO

Article history:
Received 14 February 2022
Revised 29 March 2022
Accepted 3 April 2022
Available online 6 April 2022

Keywords:
Bone metastasis
Acetabular
Harrington
Percutaneous
Minimally invasive

ABSTRACT

Classically, patients with advanced lytic disease of the acetabulum secondary to metastatic bone disease are treated with complex arthroplasty reconstruction techniques. Advancements in percutaneous techniques have extended the indications for safer, minimally invasive procedures for patients with periacetabular metastasis without the need for complex hip replacement and the complications that follow it. The purpose of this report is to revisit the management of this group of patients and provide indications for an alternative minimally invasive joint-sparing technique. We describe a novel technique using a combination of percutaneous cryoablation, cementoplasty and two-screw fixation. With careful consideration of indications, excellent functional and oncologic outcomes one year after surgery is possible without the need for additional procedures.

1. Introduction

Pain relief and restoration of ambulation are the primary goals of reconstructive procedures for patients with periacetabular insufficiency secondary to metastasis or multiple myeloma [1,2]. Classically, patients with advanced lytic disease of the acetabulum such as Metastatic Acetabular Classification (MAC) type 4 or both-column defects are treated with either a Harrington reconstruction, a cemented total hip arthroplasty (THA) and cage support or a saddle prosthesis [1,3,4]. Despite the various modifications of the Harrington procedure and the advances in prostheses and tantalum implants for increasing implant survivorship, the complication rates following these complex surgeries are high [5,6].

Indications for various cemented THA constructs in periacetabular bone disease include a defect compromising hip joint stability, a pathologic fracture, or a lesion resistant to radiotherapy [1,7]. Recently, minimally invasive techniques such as percutaneous cementoplasty and screw fixations, combined thermal ablation with cement-screw constructs, and combined osteoplasty and cryoablation have allowed for interventional procedures to go beyond the usual indications of a small contained lesion or a surgically unfit patient and to be applied even in patients with acetabular Harrington type I to III lesions with or without a minimally displaced pathologic fracture [8–11]. Muller and Capanna [3] published their treatment algorithm to address what they deemed as an under- or overtreatment in pelvic metastasis such that the Harrington classification was not the sole basis for the choice of procedure. This leaves us with an explorable gap in the indications between arthroplasty and less invasive joint-preserving techniques that minimize *peri*-operative blood loss, hip instability, and wound complications and allow for the immediate initiation of chemotherapy or radiation [11].

In this article, we revisit the management in patients with advanced pelvic and periacetabular insufficiency and provide indications for an alternative minimally invasive joint-sparing technique.

2. Surgical technique and indications

In the individual management of bone metastasis, one must always consider expected survival, tumor histology, prior systemic or radiation therapy and bony metastatic response, isolated metastasis, and presence of pathologic fracture [12]. The periacetabular area is both a unique and challenging location owing to its crucial role in load transmission [13]. Therefore, there is an urgency to restoring weight-bearing capacity that will allow painless and immediate mobility to the patient within their limited lifespan. While small acetabular lesions not involved in the weight-bearing areas (posterior column, dome, medial wall) can be treated

* Corresponding author.
E-mail addresses: ksaraneta1@gmail.com (K.T.S. Araneta), maroun.rizkallah@gmail.com (M. Rizkallah), louis-martin.boucher@mail.mcgill.ca (L.-M. Boucher), robert.turcotte@muhc.mcgill.ca (R.E. Turcotte), ahmed.aoude@mcgill.ca (A. Aoude).

https://doi.org/10.1016/j.jbo.2022.100428
2212-1374/

non-surgically, larger or more extensive lesions with or without pathologic fractures compromising stability are treated with surgical reconstruction [1]. These lesions have been historically treated with complex arthroplasty procedures. However, indications for a joint-sparing technique that combines percutaneous cryoablation, cementoplasty and screw osteosynthesis include the following:

(1) Painful lytic metastatic disease involving the acetabulum (Harrington Type I-III) that may be sensitive to radiation therapy or systemic treatment.
(2) With or without minimally displaced (<5mm) pathologic fracture or cortical dehiscence so long that the hip joint remains congruent with subchondral bone or cartilage alone.

It is equally important to note situations in which this technique is contraindicated:

(1) >5 mm displaced pathologic fracture leading to joint incongruency.
(2) Pathologic fracture leading to gross pelvic discontinuity.
(3) Significant extrusion of cement during initial ablation and cementoplasty defined as:
   - o Inability to contain enough volume of cement for adequate stability of the anterior or posterior column
   - o leakage into joint leading to mechanical block despite joint manipulation of cement

One should also exercise caution in treating radioresistant tumors. We consider it a relative contraindication, but in the context of short-term survival, this technique may still be acceptable in terms of providing palliative pain relief and mobility.

2.1. Ablation and Initial Cementoplasty

All patients selected for surgery are managed under a collaborative effort by the orthopedic surgeon and the interventional radiologist. Although in some centers, interventional radiologists also have experience in percutaneous screw fixation and in instances wherein no other orthopedic fixation is to be done (i.e. femoral nailing), the procedure may be performed by them. In our experience, if ablation is deemed appropriate this is performed first by the interventional radiologist along with an initial cementoplasty with the patient under intravenous conscious sedation (Fig. 1). Apart from symptom management, initial percutaneous ablation and cementoplasty by the interventional radiologist provides two other purposes. First it provides an assessment of containment of the lesion whereby significant cement extravasation into the hip joint would preclude further cement augmentation and joint-sparing osteosynthesis. This allows the orthopedic surgeon to determine if complex joint reconstruction would be needed the day of surgery or whether to continue with this minimally invasive technique. A range of motion (ROM) examination of the hip is necessary between the interventional procedure and the surgery in order to make the appropriate decision. Pain on ROM would mean a complex reconstruction is needed, while a painless ROM would permit the surgeon to proceed with the planned technique. The second purpose of the initial percutaneous ablation and cementoplasty is to provide a tactile landmark for the orthopedic surgeon to use intra-operatively to ensure proper percutaneous screw placement without the need for advanced imaging.

2.2. Screw insertion with augmented cementoplasty

2.2.1. Preparation and positioning

If cryoablation is performed prior, at least one hour is allowed to elapse between the ablation and surgery to allow any residual ice to thaw. This can make further cement augmentation more effective. Under general anesthesia, the patient is placed on a lateral jackknife position on a fully radioluscent table (i.e. Jackson flat top table), using a beanbag with the hips slightly flexed (Fig. 2). Rolled towels are placed between the beanbag and the patient's flank in order to laterally bend the torso away from the iliac crest. This position is crucial to ensure the torso does not get in the way of k-wire placement into the crest during surgery. Standard surgical skin preparation should be done followed by sterile draping.

Only a C-arm is required for intra-operative imaging. Initial AP, iliac and obturator oblique images are taken to visualize the extent of initial cementoplasty. We recommend at least two screws spanning the iliac crest and the initial cement mantle to allow adequate transmission of forces from the diseased periacetabular bone to the stronger iliac bone.

2.2.2. Operative technique

With the C-arm in standby position over the patient, a 3 cm incision is made along the palpable iliac crest at least 15 mm posterior to the ASIS (Fig. 3A–B). The incision is taken down to the cortex of the iliac bone. A Kelly forceps is used to widen the track to the iliac crest. A 7.3 mm drillbit is then used to open the outer cortex of the iliac crest (Fig. 5). This is followed by insertion of a blunt pedicle finder, carefully insinuating between the inner and outer iliac table, until the tip is felt to reach the initial cement mantle. A blunt probe is then used to check that the walls of the tunnel are intact. After which, a k-wire is inserted through the tunnel and subsequently drilled through the mantle.

Fluoroscopic imaging is then used to confirm the position of the k-wire by first aligning the beam with the trajectory of the k-wire (Fig. 4A, C). This initial oblique image is used to confirm that the k-

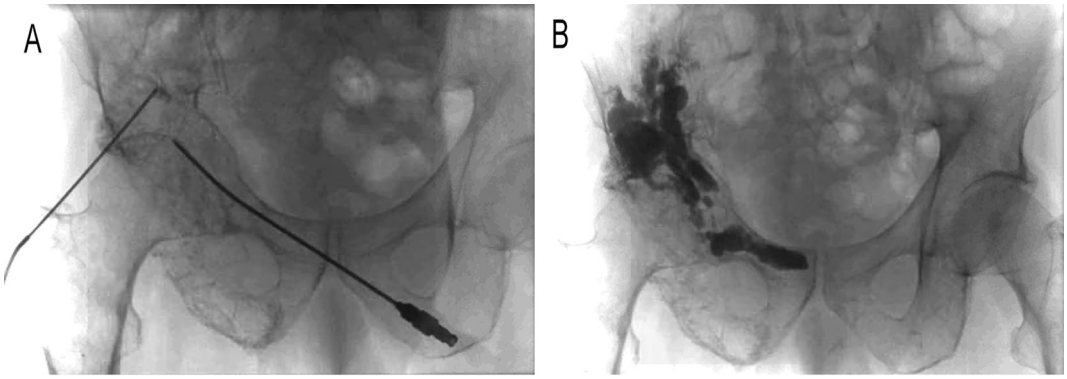

Fig. 1. A-B. Intraoperative fluoroscopic images during cryoablation and initial cementoplasty.

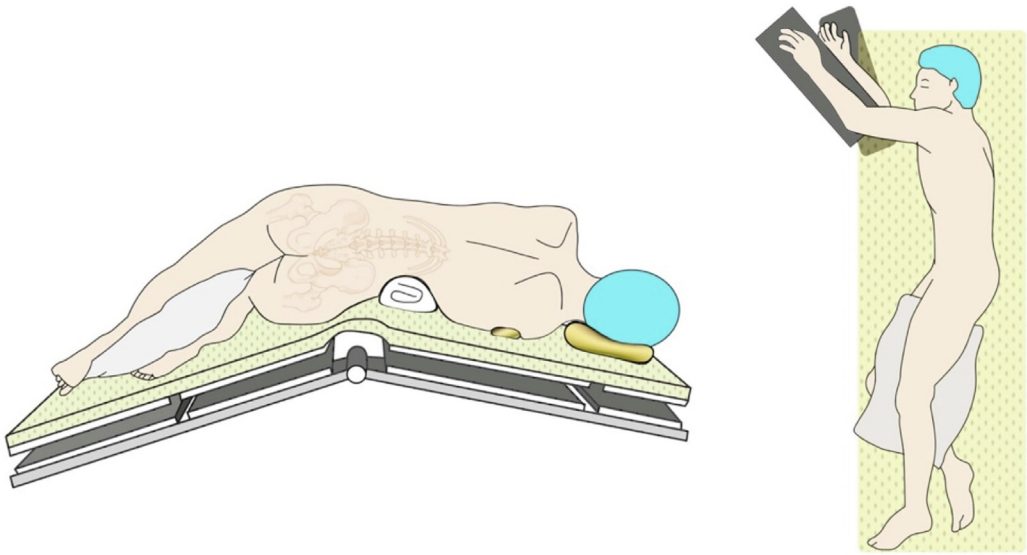

Fig. 2. Lateral jackknife position with beanbag on fully radioluscent table.

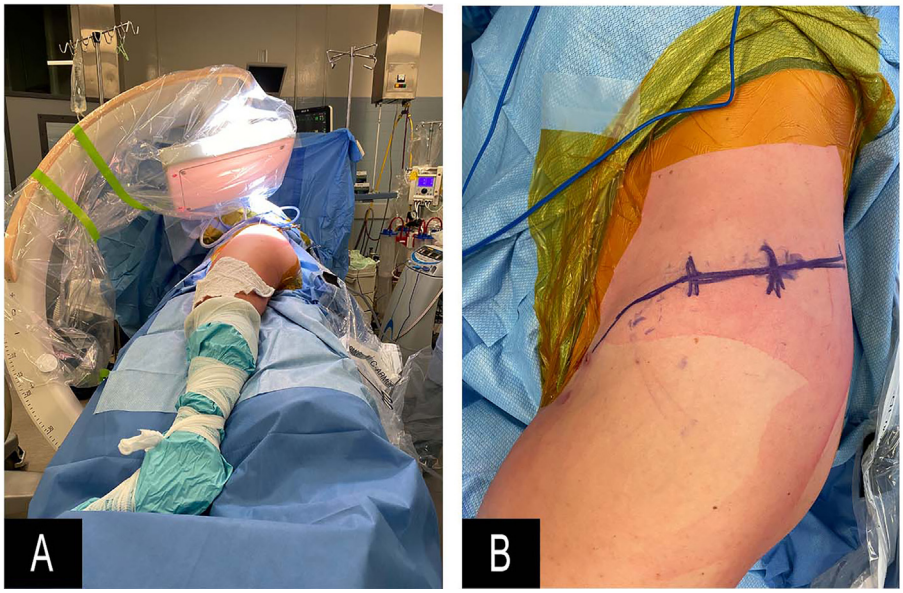

Fig. 3. A-B. (A) Patient and intraoperative C-arm positioning (B) Single incision is marked over the iliac crest.

wire is between both inner and outer tables of the ilium. A 90-degree orthogonal image along the axial plane of the patient is then taken to better visualize the placement of the k-wire in relation to the acetabular joint and iliac column (Fig. 4B, D). Once placement is deemed satisfactory, a second k-wire is inserted in a similar fashion with its entry around 1.5–2 cm posterior to the initial k-wire. Once both k-wires are seen spanning the iliac crest down to the cement mantle, we may then proceed with screw insertion.

Beginning with the anterior k-wire, drill through using the 7.3 mm cannulated drill bit making sure to reach at least halfway through the cement mantle without breaching the joint. With the k-wire still in place, screw length is measured. The appropriately sized screw is then readied on the OR table. At this point in the procedure, the surgeon should ensure that the next steps are reviewed with the surgical team and that all instruments are prepared on the table so that screw insertion is done efficiently and accurately. A misstep may lead to inadequate cement filling, premature hardening of the cement, and/or loss of the screw trajectory. We prefer to use a cement hand gun with humeral nozzle for cementation and vacuum mixing to reduce cement porosity. Once the cement is in a semi-liquid state, the nozzle (detached from the gun) is inserted directly over the k-wire down to the cement mantle. The k-wire is then quickly removed and the gun attached to the nozzle. Cement is then slowly pushed under fluoroscopic imaging to ensure no significant cement extrusion as the gun is backed up halfway. With the nozzle still in place, detach the gun once more and re-insert the k-wire through the nozzle. The appropriately measured cannulated screw is then inserted manually using a cannulated screwdriver. Final orthogonal images are then taken to confirm screw placement. The same procedure is followed for the second screw insertion. Range of motion testing of the hip is then carried out to ensure there is no crepitus or mechanical block.

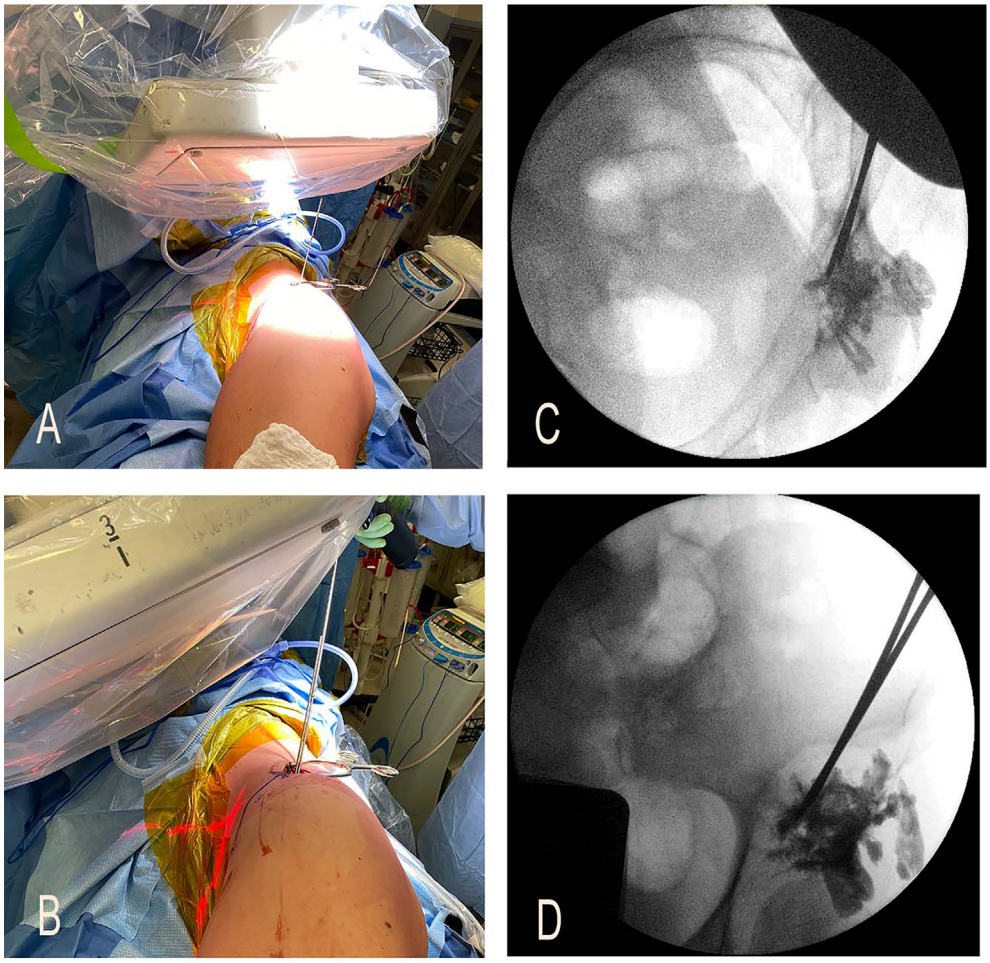

Fig. 4. A-D. C-arm positioning during k-wire insertion. After initial advancement of k-wire into cement mantle, an en-face position of the c-arm is taken (A) to demonstrate position of wire in the iliac corridor (B) This is followed by an orthogonal image by rotating the C-arm 90 degrees medially along the patient's axial plane (C) This will reveal an iliac oblique equivalent to better assess k-wire in relation to the acetabular joint (D).

Immediately after surgery, patients are allowed to weight bear as tolerated with a walker and in-patient physiotherapy is begun on post-operative Day 1. DVT prophylaxis should be resumed or initiated as well. The immediate resumption or initiation of radiation therapy and systemic therapy should be closely coordinated with the patient's medical and radiation oncologist. With current advances in systemic therapy that have prolonged survival with stable disease, radiation therapy is critical to control local disease and prevent failure of the acetabular construct.

3. Case illustrations

3.1. Case # 1

3.1.1. History and physical examination

This is the case of a 62/M diagnosed with Multiple Myeloma who presented to the clinic with persistent right hip pain for 7 months with a VAS pain score of 9/10, aggravated by weight bearing. He required a walker for ambulation and eventually became wheelchair-bound in the last 3 months. He was undergoing his 6th month of systemic chemotherapy at the time which provided initial but inadequate pain relief. On physical examination, he had a passive range of motion almost symmetric to the unaffected hip with flexion of 120 degrees, internal rotation of 10 degrees and external rotation of 30 degrees. His active ROM while lying down was limited by pain.

3.1.2. Imaging and classification

Initial pelvic radiographs reveal diffuse punched out lesions on the R hemipelvis and proximal femur with loss of the acetabular teardrop (Fig. 6A). On further investigation with a pelvic CT scan, there is a large lytic lesion involving both the anterior and, more extensively, the posterior column of the R periacetabular region (Fig. 6B–C). Although the acetabular roof appears mostly intact, there is a significant deficiency in the medial wall and quadrilateral plate as well. The soft tissue mass extends to the ischial tuberosity, thinning out most of the cortex with the presence of multiple cortical breaches. There are also multiple lytic lesions over the femoral head and proximal femur. There remains congruency in the acetabulofemoral joint. This is a MAC type 4 showing both column defects of the R periacetabular region.

3.1.3. Treatment

Given the extent of periacetabular disease, cortical stability is severely compromised beyond treatment with radiotherapy. Stabilization of the acetabulum is now the primary goal along with pain control. Indications for a combined minimally invasive treatment approach for this patient include a congruent hip joint despite lesions in the proximal femur and acetabulum and the absence of gross displacement of pathologic fractures. The extent of cortical

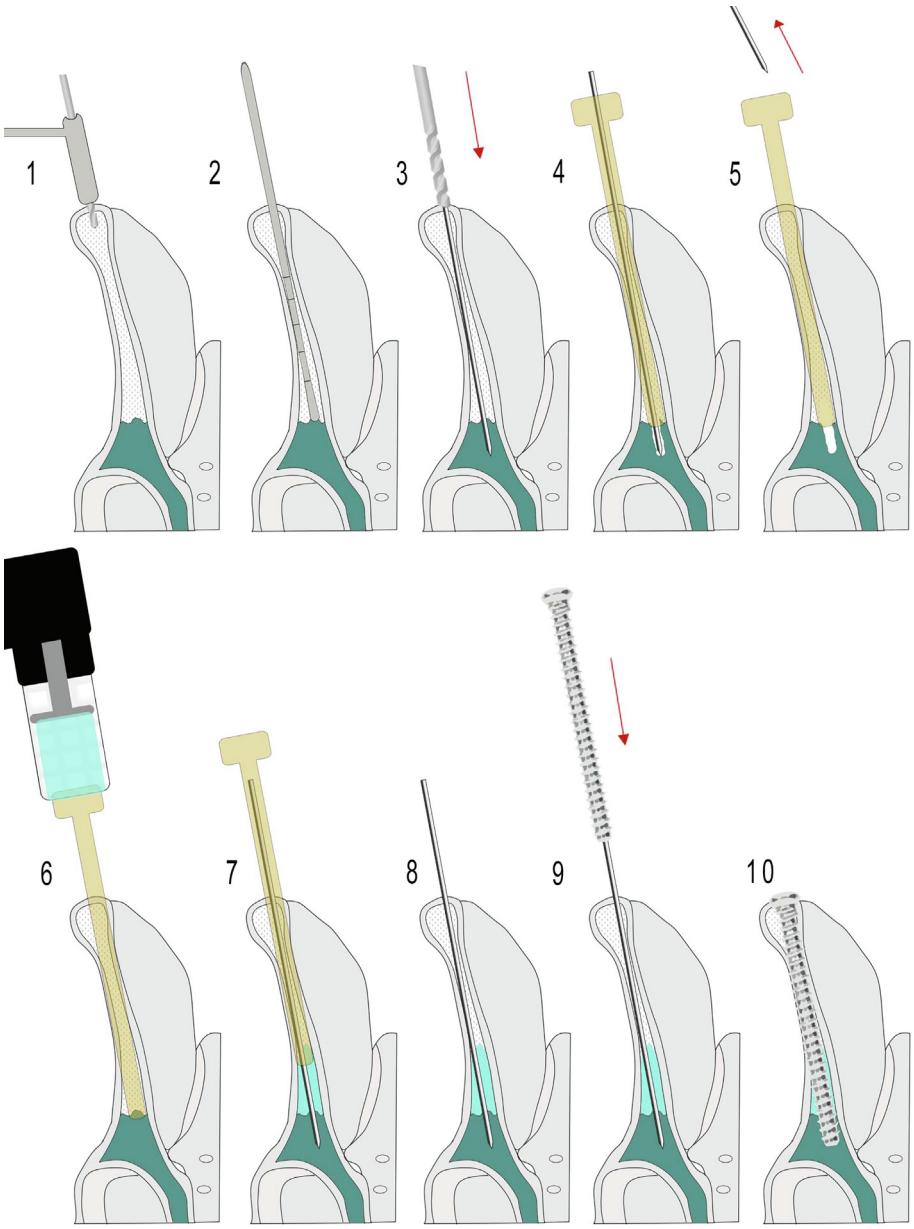

Fig. 5. Steps for percutaneous screw insertion and augmented cementoplasty. Drill outer cortex of iliac crest (1) Insinuate the pedicle finder between inner and outer iliac table until initial cement mantle is palpable (2) Insert k-wire through the tunnel made by the pedicle finder through to the mantle and drill with cannulated drillbit (3) Exchange k-wire with appropriately sized nozzle and push semi-liquid cement with cement gun (4–6) Backup nozzle slightly and quickly exchange with k-wire to insert pre-measured cannulated screw (7–10).

dehiscence despite both columns being affected was not a contraindication to this procedure. An alternative invasive procedure was also considered; one that would require patient-specific custom hemipelvic implant. However, this would have increased the risk of morbidity, delayed the surgery for the custom implant to be manufactured and delayed the systemic therapy for at least two weeks after the surgical intervention if no complications were to occur. Considering all this, it was decided with the patient to proceed with the minimally invasive ablation, cementoplasty and screw augmentation. The rational was if this procedure failed then a custom implant could always be reconsidered.

This patient underwent percutaneous cryoablation and cementoplasty by interventional radiology and subsequent prophylactic intramedullary nailing of the ipsilateral femur with periacetabular cement augmentation and screw osteosynthesis (Fig. 7A–B). He tolerated both procedures well and had an uneventful recovery at the post-anesthesia care unit. Total surgical time was 3 h with an estimated blood loss of 350 ml mostly from the intramedullary reaming during intramedullary nail insertion of the ipsilateral femur.

3.1.4. Outcomes

On post-operative Day 1, the patient was able to do sitting and standing activities with minimal assistance. Pain was reported VAS 0–1/10 given he was on epidural pain medication. By the 3rd post-operative day, he was able to ambulate with a walker. His epidural catheter was discontinued on the 4th day, by which time the patient was already able to climb stairs up and down. He was discharged with a walker and on oral pain medications on his 6th hospital day. By his first week after surgery, no narcotic medications

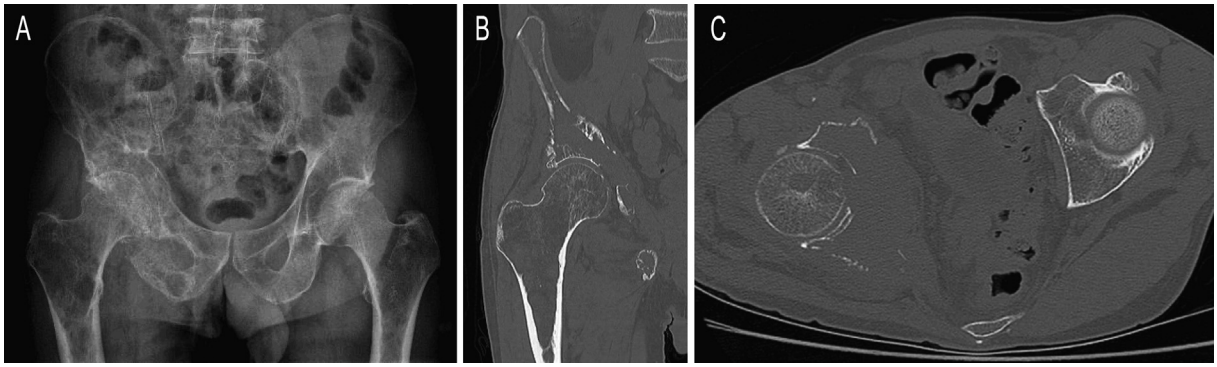

Fig. 6. A-C. (A) Preoperative radiographs reveal multiple punched out lesions of the R hemipelvis and proximal femur (B) Pre-operative Coronal CT images show the defective medial wall on the R acetabulum along with thinned out cortices (C) Sagittal CT images showing extent of lysis involving the quadrilateral plate, anterior and posterior columns. A femoral head lytic lesion is also seen on this cut.

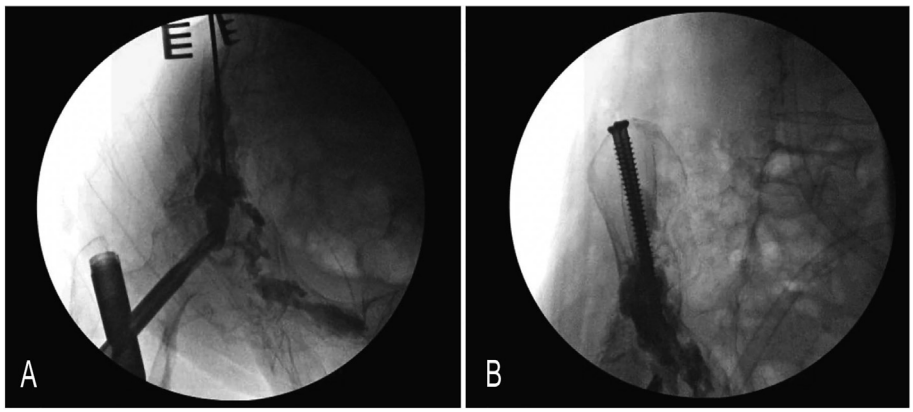

Fig. 7. A-B. (A) Intraoperative fluoroscopic imaging showing insertion of k-wire guide from iliac crest to the supraacetabular region. (B) Placement of two cannulated screws soon after addition of cement into the screw holes.

were required and he was only on an acetaminophen as needed regimen. Chemotherapy was resumed 2 weeks after surgery. After 1 month, patient reported minimal pain and only required a cane for ambulation. He also received post-operative radiotherapy to the right hemipelvis. The patient then underwent a bone marrow transplant procedure 4 months after surgery, at which time he was already ambulating independently without any aids. At 1 year, patient has stable disease and continues to ambulate without pain and with functional active and passive range of motion as follows: 110 degrees hip flexion, 70 degrees hip abduction, 10 degrees internal rotation, and 80 degrees external rotation. He is able to perform straight leg raises and squats. Post-operative radiographs at this time show no loosening of the implants and an intact joint (Fig. 8).

3.2. Case # 2

3.2.1. History and physical examination

This is the case of a 49/F diagnosed with invasive ductal carcinoma of the right breast who underwent partial mastectomy, adjuvant chemotherapy and external beam radiation therapy 6 years prior. She then developed progressive pain on the left hip for 9 months before an MRI revealed a new lesion on the left iliac wing, confirmed to be metastatic invasive ductal carcinoma, ER/PR positive and HER-2/neu negative on CT-guided biopsy. She was then initiated on aromatase inhibitors. Patient was on hydromorphone 2 mg every 2–4 h with minimal relief of hip pain. At the time of physical examination, she had a VAS pain score of 10/10.

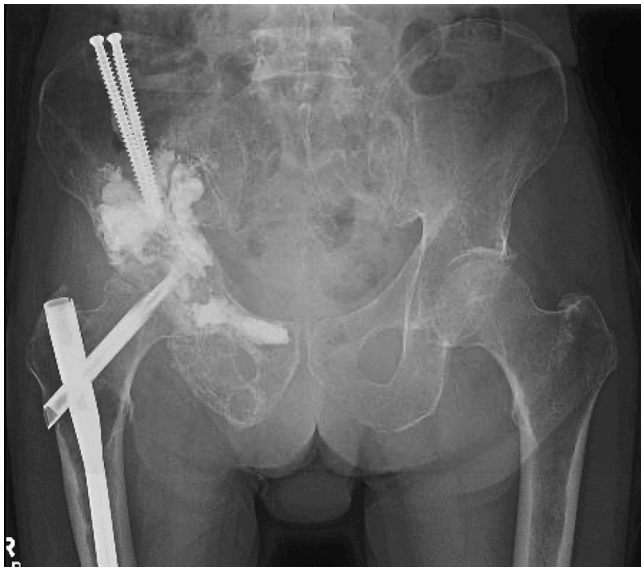

Fig. 8. Postoperative radiographs at 1 year showing the intact cement-screw construct and stable TFN with no evidence of metastatic progression or loosening of implants.

She had been unable to bear weight on her left lower extremity and range of motion could not be assessed due to the excruciating pain. She had no lymphadenopathies or neurologic deficits. The rest of her physical examination was normal.

3.2.2. Imaging

On CT scan of the pelvis there was a large lytic lesion measuring 5.0 × 2.3 × 4.3 cm within the supraacetabular region with breaching of the cortex of the anterior column medially and thinning of the subchondral bone over the dome (Fig. 9A–B). We classified this as a MAC Type 3a.

3.2.3. Treatment

Following similar indications as the previous case, this patient developed extensive insufficiency over the weightbearing aspect of her acetabulum. In order to stabilize this area, a combined cryoablation and cementoplasty was performed by interventional radiology (Fig. 10) followed by additional cementation and screw augmentation by the orthopedic team using the same minimally invasive technique as the first case (Fig. 11B). It was difficult to get a complete cementation of the lesion during the initial cementoplasty. Some cement leaked into the periosseous tissues posterolateral to the acetabulum (Fig. 10B), but not involving the joint space or other critical structures. There were no immediate complications and patient tolerated both procedures well. Additional cementation during surgery provided additional stability. Total surgical time was 2 h with an estimated blood loss of < 10 ml.

3.2.4. Outcomes

Five hours following the surgery, the patient was ambulating with a walker at the recovery room. She reported 0/10 VAS pain at rest and 5/10 on ambulation. She was on patient-controlled analgesia with hydromorphone. She was discharged on her 3rd post-operative day after being able to ambulate up and down the stairs with a cane. She left the hospital on narcotic oral pain medication. By 2 weeks, she underwent radiotherapy to the L hip. One month after surgery she no longer required narcotic pain medication and was on acetaminophen as needed. At 2 months, she reports only occasional use of her cane and a VAS pain score of 1–2. In 6 months, she was independently ambulating without any assistive devices and did not complain of any groin pain. One year after the surgery, the patient continues to be functionally independent and pain-free while a PET/CT scan showed stable disease. Comparative radiographs (Fig. 11A–C) show a stable construct with no progression of local disease.

Fig. 9. A-B. A) Pre-operative Coronal CT images show a large supraacetabular lytic lesion (B) Axial CT images showing anterior column extent with breaching of inner table.

4. Review of the literature

The nature of malignant tumors or the bony instability related to their spread can cause excruciating pain and morbidity [14,15]. The debilitating pain and the loss of functional activities that follow despite nonsurgical management or interventional procedures like percutaneous cementoplasty and radiofrequency or cryoablation are indications for surgical management [1,10]. Because both metastatic tumors and multiple myeloma are mostly sensitive to radiation therapy, these do not necessitate an en bloc removal but rather an intralesional approach in addition to adjuvant radiation therapy for addressing residual disease [2,16].

Metastatic disease accounts for nearly half of the tumor pathologies in periacetabular reconstructions in the literature, while multiple myeloma has been seen in 2% of cases [5]. Several authors have advocated algorithms in the surgical management of periacetabular disease based on different classification systems or a combination of those classification systems (Table 1). While the Harrington classification and MAC system are based on radiologic images, Muller and Capanna's classification takes into additional consideration prognosis, disease-free interval since detection of primary, and whether lesions are osteoblastic or osteolytic. However, what is common across all classifications, is that the minimum threshold for proceeding with a joint replacement would be any defect compromising hip joint stability, a pathologic fracture, or a lesion resistant to radiotherapy [1,4,7,13].

Recent concerns have been raised by some authors regarding the criteria for joint replacement in patients with metastatic periacetabular lesions. Powell and Ardestani [14] pointed out that thermal ablation with screw osteoplasty has been successful even in patients with up to Harrington type III lesions as in the study by Hartung et al. [10] and that not all studies on patients treated with the Harrington procedure give clear indications for a joint replacement. English et al. [11] most recently published a retrospective series of 38 patients with periacetabular metastatic disease managed with minimally invasive cementoplasty and screw fixation that included those with pathologic minimally displaced fractures or impending fractures, with or without ablation. This group included Harrington types II-III lesions. None of their patients developed perioperative infection, instability, clots, or blood loss requiring transfusion. Only 6 out of 38 required repeat intervention of which only 3 (8%) underwent a subsequent joint replacement with no postoperative complications. The remaining 3 were treated with repeat minimally invasive treatment with resolution of symptoms. The "screw and glue" technique they used was that originally described by Lea et al. [17] wherein 3 screw corridors are utilized to provide a "base" support for fixation. Their study demonstrated the success of this treatment as both a definitive procedure even for patients that may otherwise have been surgical candidates for arthroplasty or a bridge procedure for said patients so that adjuvant treatment is not delayed. Given that surgical options such as the Harrington reconstruction, cemented THA and cage support or a saddle prosthesis have consistently high rates of complications across the literature [5,6], it is worthwhile

Fig. 10. A-B. (A) The ablation was performed with fluoroscopic guidance placing a 13G vertebroplasty needle into the left supraacetabular lesion (B) ablated lesion then filled with bone cement.

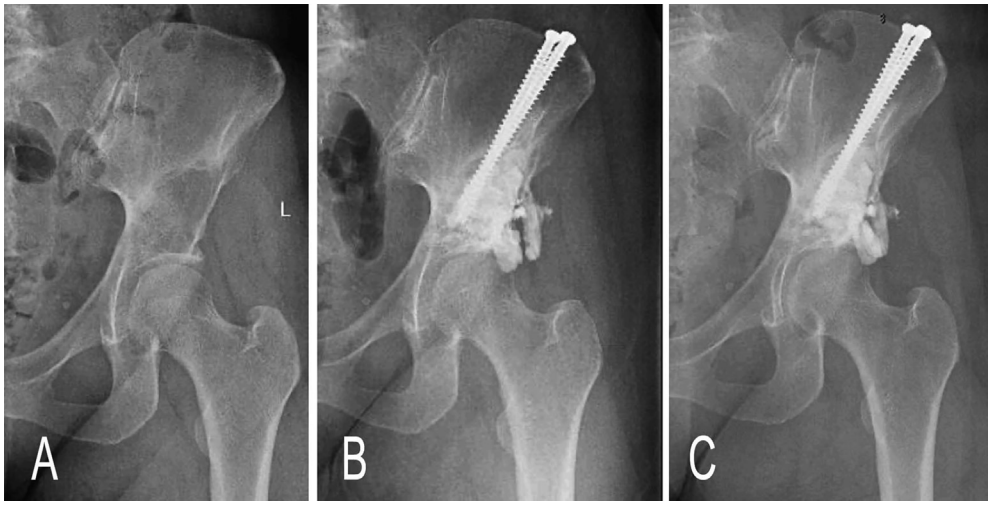

Fig. 11. A-C. (A) Pre-operative radiographs and (B) 6 months after surgery showing an intact cement-screw construct (C) 1 year after surgery showing stable appearance.

to revisit their indications and consider less invasive but successful interventional procedures as discussed.

Interventional techniques like percutaneous cementoplasty and thermal ablation have been typically useful in patients with metastatic acetabular lesions without impending fractures or instability, who experience refractory pain to radiation therapy and medical management, and/or are non-surgical candidates [1,13,18]. With the addition of screws to the percutaneous osteoplasty technique, some surgeons have extended this indication to include impending fractures, minimally displaced fractures and unstable lesions involving the posterior or anterior column [8,10,11,14,17,19]. The limits of percutaneous cementoplasty with screw augmentation in terms of the size of the osteolytic lesions and cortical disruption have not been well established. The case report by Powell and Ardestani [14] involved two patients both post-remission with periacetabular insufficiency, one from metastatic breast carcinoma and another from multiple myeloma, with cavities measuring at least 8 cm in diameter accompanied by various areas of cortical disruption on both columns. After treatment with cement osteoplasty with screw augmentation, there was no leakage of cement at the sites of cortical loss as confirmed by CT images and both patients had excellent pain relief and restoration of mobility within a week or month. In addition, the previously mentioned series by English et al. [11] did not consider cortical dehiscence in the articular area of the acetabulum as a contraindication for cementoplasty despite risks of joint extravasation. Unfortunately, their study did not mention tumor size or volume for means of comparison. Three patients who had cement extrusion had no symptoms post-operatively. Lea et al. [17] further qualifies that although most are inconsequential, small leaks into the hip joint may be smoothened out by manipulating the hip.

While a number of authors have described percutaneous cementoplasty and screw osteosynthesis with or without ablation in patients with pelvic insufficiency [8,11,14,17,19], only two authors have dealt with the use of this technique specifically on periacetabular metastatic disease (Table 2, Figs. 12–13). English et al. [11] later on published their series based on that described by Lea et al. [17]. These studies involved patients with advanced periacetabular involvement (up to Harrington III lesions) and similar exclusion criteria such as those with gross pelvic discontinuity and > 5 mm displacement of acetabular fractures. The advantages these studies have shown are significant since the morbidity from complex arthroplasty procedures are avoided leading to few complications, short hospital stay, minimal blood loss, and immediate initiation of adjuvant radio- or chemotherapy [10,11].

What primarily sets this technique apart from other minimally invasive techniques in the literature is its technical simplicity making it especially useful in hospitals without advanced fluoroscopic

Table 1
Surgical treatment algorithms for periacetabular insufficiency [1,3,4,7].

Article	Classification Used	Type	Treatment
Harrington, 1981	Harrington	I - disrupted articular congruity, intact walls and columns II – deficient medial wall and quadrilateral plate III – deficient roof and acetabular rim IV – periacetabular resection; pelvic discontinuity	Curettage + Conventional Cemented THA Cemented THA + flanged cup Harrington Procedure Harrington Procedure ± sterilized resected bone
Brown and Healey, 2015	MAC	1a – cavitary lesion in dome or roof of acetabulum but intact subchondral bone	Bipolar HA, cementation of lesion Cemented THA ± flanged cup/protrusio ring
		1b – insufficient subchondral bone 2a – medial wall deficiency without dome defects	THA + flanged cup or cage ± reinforced cement
		2b – medial wall deficiency with dome and/or medial wall defects	Cemented THA + flanged cup/protrusio ring
		3a – single column defect without dome/medial wall defects	Cemented THA ± flanged cup/protrusio ring
		3b - single column defect with dome and/or medial wall defects	Cemented THA and flanged cup/protrusio ring
		4 – both column defect	Cemented THA ± flanged cup/protrusio ring depending on dome or medial wall defect Saddle prosthesis
Issack, Kotwal, Lane, 2013	MAC and Harrington	MAC 1, Harrington I	Cementation of lesion + THA
		MAC 2, Harrington II, Harrington III MAC 3 or 4, Harrington III	Cemented THA + flanged cup/cage Harrington procedure / Cemented THA + cage / Saddle prosthesis
Muller and Capanna, 2015	Capanna	1 - Solitary metastatic lesion; Primary with good prognosis; Interval > 3 years since detection of primary	Harrington Procedure Megaprosthesis Saddle Prosthesis Massive allograft with THR
		2 – Pathologic fracture in periacetabular region 3 – Supra-acetabular osteolytic lesion	*Harrington I defect:* Curettage, cement Conventional THA *Harrington II defect:* THA with reinforcement ring *Harrington III defect:* Harrington procedure Defect filling with cement or allograft and THA *Harrington IV defect:* Megaprosthesis Saddle Prosthesis Massive allograft with THR
		4 – Multiple osteoblastic lesions at all sites; Small radiosensitive periacetabular osteolytic lesions	Non-surgical management: Chemotherapy, hormonal therapy, and/or irradiation

equipment. A minimum of 2 cannulated screws inserted from the iliac crest can provide adequate stability with additional cementation, thereby requiring only basic instrumentation and fluoroscopy (Table 2, Fig. 14). The combined construct of the cement and screws allows the transmission of weight-bearing stresses from the deficient medial wall and weakened roof into intact iliac bone as is the principle of the original Harrington technique. The target of the screws should be the cement mantle contained in the weight bearing area of the acetabulum. Outside of this area, we do not believe screw osteosynthesis is necessary. This is confirmed by the biomechanical principle that the sacroiliac joint, iliac wing, pubis, and ischium have very little contribution to weight-bearing capacity [13]. In the absence of pathologic fracture displacement in these less vital areas, cement can provide enough compressive support and pain control owing to its thermal and cytotoxic effect on tumor [13].

The successful screw insertion techniques by Hartung et al. [10], English et al. [11] and Lea et al. [17] are effective but require advanced intra-operative imaging with either combined CT and augmented fluoroscopy or O-arm. Pre-operative planning of screw placement and insertion is more technically demanding given the registration of 3D objects with augmented fluoroscopy. Lea et al [17] noted operative times and radiation exposure can be high given the complexity and frequency of its use. In this new technique x-ray exposure is kept to a minimum and average surgical time for all cases has been under 2 h with a minimal blood loss which we believe will decrease morbidity even further.

Our indications for this combined approach are similar to previous authors (i.e. no gross pelvic discontinuity, <5mm displacement of pathologic fractures) with the addition that joint congruency be taken into consideration when doing a hip-sparing procedure as opposed to an immediate arthroplasty. Significant cement extravasation into the joint during initial cementoplasty by the interventional radiologist is also a contraindication to proceeding with a joint-sparing procedure. Problematic cement extrusions can be assessed prior to orthopedic screw fixation and cement augmenta-

tion by doing a simple physical examination as mentioned in the detailed technique, allowing the surgeon to decide the ideal surgery to proceed with for each given patient. In certain cases, the indication for this type of procedure can be expanded to include early acetabular lesions seen in initial staging images, especially in high risk areas such as the supraacetabular dome, posterior column or medial wall. Ultimately the decision to extend the indication should be discussed on a case-to-case basis with the patient, taking into consideration symptomatology, tumor histology, expected response, and prognosis.

Table 2
MIS Techniques combining ablation, cementoplasty and osteoplasty in periacetabular metastatic disease [10,11,17].

Author - Year	Adjuvant Intervention	Principle	Screw Entry Sites	Imaging equipment for screw insertion	Construct
Hartung et al. 2016	RFA or cryoablation	Transmission of weight-bearing forces of acetabulum from diseased periacetabular bone to structurally intact bone within pelvis	Same as ablation portals when possible. Ischial tuberosity; pubic tubercle; between greater trochanter and iliac crest; anterior inferior iliac spine (AIIS)	CT, combined CT/ fluoroscopy, O-arm	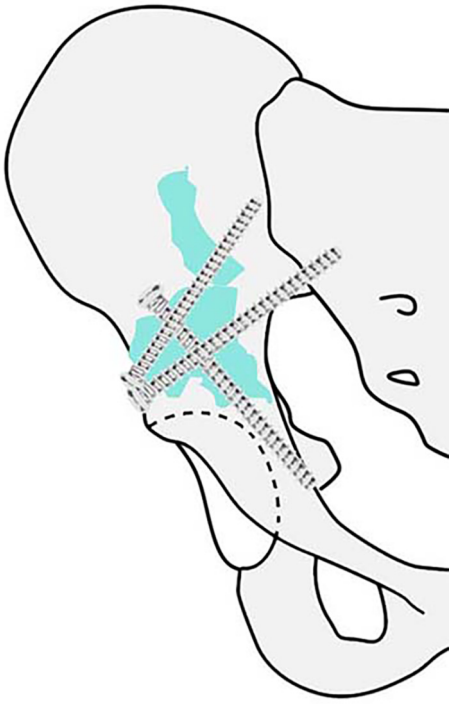
Lea et al. 2019	RFA or cryoablation	Use of cement-rebar phenomenon	Ischium, superior ramus, AIIS in 3 primary corridors	Augmented fluoroscopy with overlaying 3D CT imaging	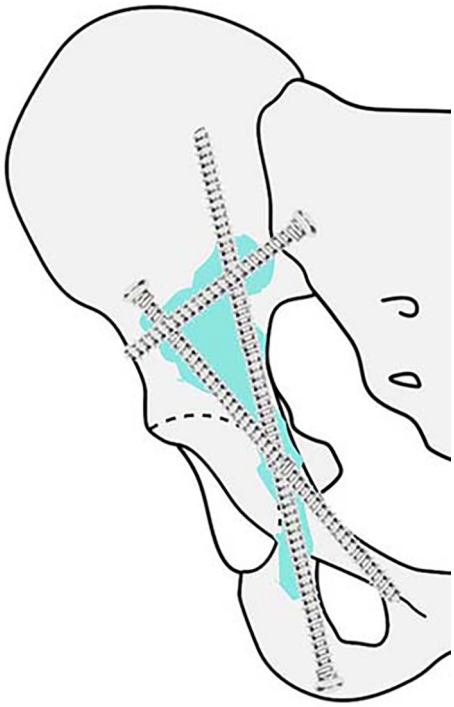

Table 2 (*continued*)

Author - Year	Adjuvant Intervention	Principle	Screw Entry Sites	Imaging equipment for screw insertion	Construct
Present article	RFA or cryoablation	Transmission of forces from the weight-bearing aspect of the acetabulum to intact bone within the ilium	Iliac crest	C-arm	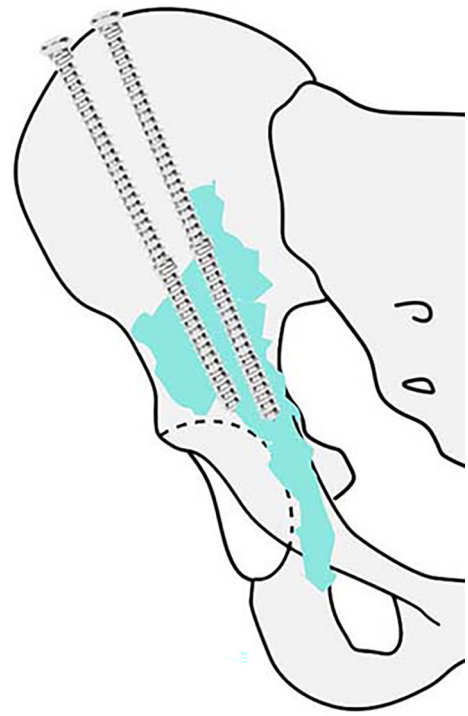

5. Conclusions

Advancements in percutaneous techniques have extended the indications for safer, minimally invasive procedures for patients with periacetabular metastasis without the need for complex hip replacement and the complications that follow it. Surgeons need to meticulously reassess their indications for arthroplasty when using the Harrington or MAC classification to avoid overtreatment of lytic periacetabular lesions. Cortical defects seen on CT imaging do not necessarily translate to lack of containment for cementoplasty as seen in our cases and other published reports where there remains an intact periosteal envelope or cartilage that prevents cement leakage. This article illustrates how with careful consideration of indications, even patients with extensive periacetabular destruction can be successfully treated with a hip-sparing minimally invasive reconstruction of the acetabulum using a combination of cryoablation, percutaneous cementoplasty and two-screw fixation. Excellent functional outcomes one year after surgery is possible without the need for additional procedures. In addition, this technique is considered to be revisable to more invasive hip reconstructions at later stages if they fail. Like other combined percutaneous techniques, it can also help treat patients with less morbidity associated with surgery, initiate systemic treatment and/or radiation earlier which may lead to overall better outcomes. We suggest that this technique be used as a primary modality for treatment while conventional arthroplasty techniques be used as a secondary option in select patients with advanced periacetabular metastasis.

Declaration of Competing Interest

The authors declare that they have no known competing financial interests or personal relationships that could have appeared to influence the work reported in this paper.

References

[1] P.S. Issack, S.Y. Kotwal, J.M. Lane, Management of Metastatic Bone Disease of the Acetabulum, J. Am. Acad. Orthop. Surg. 21 (11) (2013) 685–695, https://doi.org/10.5435/JAAOS-21-11-685.
[2] V.I. Sakellariou, A.F. Mavrogenis, O. Savvidou, F.H. Sim, P.J. Papagelopoulos, Reconstruction of multiple myeloma lesions around the pelvis and acetabulum, Eur. J. Orthop. Surg. Traumatol. 25 (4) (2015) 643–653, https://doi.org/10.1007/s00590-014-1555-4.
[3] D.A. Müller, R. Capanna, The Surgical Treatment of Pelvic Bone Metastases, Adv. Orthop. 2015 (2015) 1–10, https://doi.org/10.1155/2015/525363.
[4] H. Brown, J. Healey, 2.15 Pathological pelvic fractures and acetabular reconstruction in metastatic disease, in: M. Tile, D.L. Helfet, J.F. Kellam, M. Vrahas (Eds.), Fractures of the Pelvis and Acetabulum, 4th ed., Georg Thieme Verlag, Stuttgart, 2015, pp. 838–848, https://doi.org/10.1055/b-0035-121667.
[5] T.S. Brown, C.G. Salib, P.S. Rose, F.H. Sim, D.G. Lewallen, M.P. Abdel, Reconstruction of the hip after resection of periacetabular oncological lesions, Bone Joint J. 100-B (1_Supple_A) (2018) 22–30, https://doi.org/10.1302/0301-620X.100B1.BJJ-2017-0548.R1.
[6] N.M. Bernthal, S.L. Price, M.J. Monument, B. Wilkinson, K.B. Jones, R.L. Randall, Outcomes of Modified Harrington Reconstructions for Nonprimary Periacetabular Tumors: An Effective and Inexpensive Technique, Ann. Surg. Oncol. 22 (12) (2015) 3921–3928, https://doi.org/10.1245/s10434-015-4507-2.
[7] K.D. Harrington, The management of acetabular insufficiency secondary to metastatic malignant disease, J. Bone Joint Surg. Am. 63 (4) (1981) 653–664.
[8] F. Deschamps, T. de Baere, A. Hakime, E. Pearson, G. Farouil, C. Teriitehau, L. Tselikas, Percutaneous osteosynthesis in the pelvis in cancer patients, Eur. Radiol. 26 (6) (2016) 1631–1639, https://doi.org/10.1007/s00330-015-3971-1.

[9] A.N. Kurup, J.M. Morris, G.D. Schmit, T.D. Atwell, J.J. Schmitz, P.S. Rose, M.R. Callstrom, Balloon-Assisted Osteoplasty of Periacetabular Tumors following Percutaneous Cryoablation, J. Vasc. Interv. Radiol. 26 (4) (2015) 588–594, https://doi.org/10.1016/j.jvir.2014.11.023.

[10] M.P. Hartung, S.M. Tutton, E.J. Hohenwalter, D.M. King, J.C. Neilson, Safety and Efficacy of Minimally Invasive Acetabular Stabilization for Periacetabular Metastatic Disease with Thermal Ablation and Augmented Screw Fixation, J. Vasc. Interv. Radiol. 27 (5) (2016) 682–688.e1, https://doi.org/10.1016/j.jvir.2016.01.142.

[11] D.I. English, W.B. Lea, D.M. King, S.M. Tutton, J.C. Neilson, Minimally Invasive Stabilization with or without Ablation for Metastatic Periacetabular Tumors, J. Bone Joint Surg. 103 (2021) 1184–1192, https://doi.org/10.2106/JBJS.20.00546.

[12] A. Angelini, G. Trovarelli, P. Ruggieri, Metastases to the Pelvis: Algorithm of Treatment, in: V. Denaro, A. di Martino, A. Piccioli (Eds.), Management of Bone Metastases, Springer International Publishing, Cham, 2019, pp. 104–110, https://doi.org/10.1007/978-3-319-73485-9.

[13] W. Al-Hardan, E. Garbrecht, K. Huntley, J. Pretell-Mazzini, Surgical Management Update in Metastatic Disease of the Pelvis Operative Techniques in Orthopaedics, Oper. Techniques Orthop. 31 (3) (2021) 100897, https://doi.org/10.1016/j.oto.2021.100897.

[14] D.K. Powell, A. Ardestani, Percutaneous screw-reinforced cement osteoplasty for palliation of postremission pain in larger lytic sacro-acetabular iliac cavities, Radiol. Case Rep. 14 (9) (2019) 1093–1099, https://doi.org/10.1016/j.radcr.2019.06.009.

[15] P. Birthi, P. Sloan, Interventional Treatment of Refractory Cancer Pain, Cancer J. 19 (2013) 390–396, https://doi.org/10.1097/PPO.0b013e3182a631a2.

[16] J. Bickels, M.M. Malawer, Chapter 20: Surgical Management of Metastatic Bone Disease: Pelvic Lesions, in: S.W. Wiesel, M.M. Malawer, J.C. Wittig, J. Bickels (Eds.), Operative Techniques in Orthopaedic Surgical Oncology, 2nd ed., Lippincott Williams & Wilkins, 2016: p. 372.

[17] W.B. Lea, J.C. Neilson, D.M. King, S.M. Tutton, Minimally Invasive Stabilization Using Screws and Cement for Pelvic Metastases: Technical Considerations for the Pelvic "Screw and Glue" Technique, Seminars in Interventional Radiol. 36 (03) (2019) 229–240, https://doi.org/10.1055/s-0039-1693982.

[18] T.M. Coupal, K. Pennycooke, P.I. Mallinson, H.A. Ouellette, P.W. Clarkson, P. Hawley, P.L. Munk, The Hopeless Case? Palliative Cryoablation and Cementoplasty Procedures for Palliation of Large Pelvic Bone Metastases, Pain Physician. 20 (2017) E1053–E1061.

[19] C. Pusceddu, A. Fancellu, N. Ballicu, R.M. Fele, B. Sotgia, L. Melis, CT-guided percutaneous screw fixation plus cementoplasty in the treatment of painful bone metastases with fractures or a high risk of pathological fracture, Skeletal Radiol. 46 (4) (2017) 539–545, https://doi.org/10.1007/s00256-017-2584-y.